





Case Report

Primary Intracranial Oligosarcoma with IDH2 Mutation:
A Rare Case Report

 Muhammed Şamil Sağlam¹,  Muhammed Erkam Yüksek²,  Naile Kökbudak³,  Mehmet Fatih Erdi⁴

¹Necmettin Erbakan University Meram Faculty of Medicine, Department of Neurosurgery, Konya, Türkiye

²Konya City Hospital, Clinic of Neurosurgery, Konya, Türkiye

³Necmettin Erbakan University Meram Faculty of Medicine, Department of Pathology, Konya, Türkiye

⁴Necmettin Erbakan University Meram Faculty of Medicine, Department of Neurosurgery, Konya, Türkiye

ABSTRACT

Oligosarcoma is a rare malignant tumor of oligodendroglial origin that exhibits sarcomatous components and histological features consistent with World Health Organization grade III gliomas. Sarcomatous transformation of oligodendroglial components has only been reported in a small number of cases to date. In this report, we present a unique case of primary oligosarcoma diagnosed by histopathological examination after surgical resection.

Keywords: Oligosarcoma, oligodendrogloma, sarcomatoid transformation

Introduction

Oligosarcoma is a rare malignant tumor derived from oligodendroglial origin, exhibiting sarcomatous components and histological features consistent with World Health Organization grade III gliomas [1]. Oligodendrogloma is generally considered a relatively indolent neoplasm with a better prognosis than astrocytic tumors [2,3]. It accounts for approximately 0.5-1.2% of all primary brain tumors and histologically exhibits the classic “fried egg” appearance, characterized by smooth, round nuclei surrounded by prominent perinuclear halos. At the molecular level, its most distinctive feature is a deletion of all arms of chromosomes 1p and 19q (1p/19q codeletion), which is associated with increased response rates to chemotherapy and survival exceeding 14 years [2,4]. Although transformation to higher-grade lesions such as anaplastic oligodendrogloma has been described, sarcomatous transformation is extremely rare. The majority of oligosarcoma cases are reported as recurrences of previously diagnosed and treated oligodendroglomas. Therefore, the occurrence of an oligosarcoma as a primary presentation is exceptional and should be evaluated with caution. Of the 36

oligosarcoma cases reported in the literature, only 5 were primary, with the remainder developing in the setting of previously resected oligodendrogloma or oligoastrocytoma [5]. This highlights the extremely rare occurrence of *de novo* oligosarcoma.

Case Report

A 69-year-old man presented with headache, unsteadiness, and urinary incontinence. The patient had no prior brain imaging studies. The patient also had no known pre-existing brain pathology or history of radiotherapy. Computed tomography of the brain revealed a tumor with calcification in the right frontal lobe. Radiologically, the tumor appeared hyperintense on T2-weighted imaging, hypointense on T1-weighted imaging, and showed contrast enhancement on gadolinium-enhanced T1-weighted imaging. Oligodendrogloma was suspected. Written informed consent was obtained from the patient for the surgical procedure and for the publication of this case report and case images. The mass was grossly excised using an interhemispheric approach (Figure 1). After the initial surgery, the histopathological diagnosis was oligosarcoma with IDH2

Address for Correspondence: Muhammed Şamil Sağlam MD, Necmettin Erbakan University Meram Faculty of Medicine, Department of Neurosurgery, Konya, Türkiye

E-mail: saglamsamil@gmail.com **ORCID ID:** orcid.org/0009-0001-8416-1455

Received: 10.11.2025 **Accepted:** 05.02.2026 **Epub:** 12.03.2026 **Publication Date:** 08.04.2026

Cite this article as: Sağlam MŞ, Yüksel ME, Kökbudak N, Erdi MF. Primary intracranial oligosarcoma with IDH2 mutation: a rare case report. Acta Haematol Oncol Turc. 2026;59(1):59-62



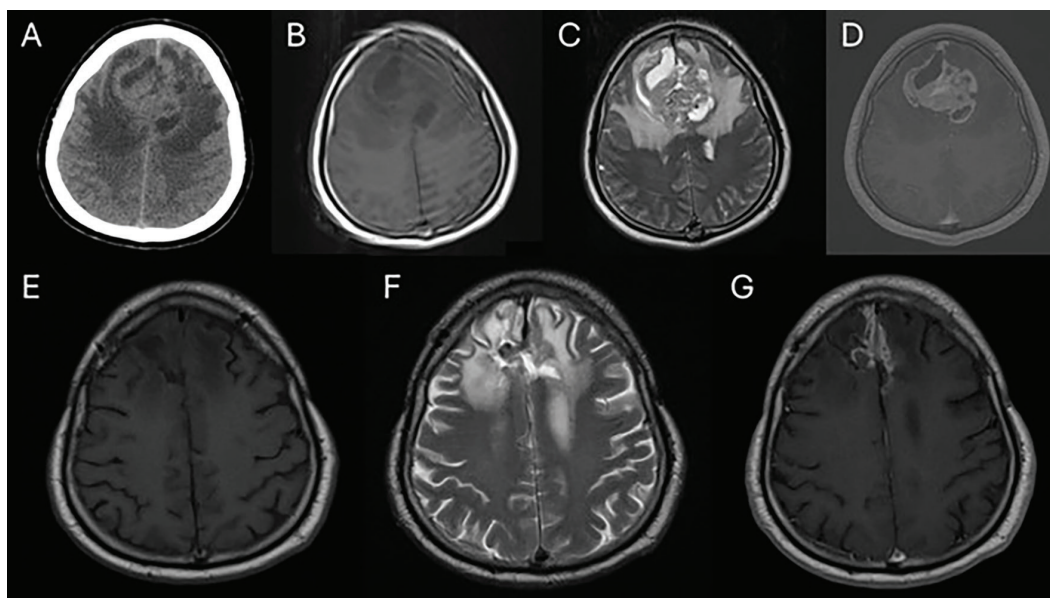


Figure 1. Preoperative (A-D) and postoperative (E-G) images of the first surgery. A: Cranial CT scan shows the frontal lobe lesion. T1-weighted (B), T2-weighted (C), and contrast-enhanced T1-weighted MRI (D) show the frontal mass. Postoperative MRI images [T1-weighted (E), T2-weighted (F), and contrast-enhanced T1-weighted magnetic resonance images (G)] show the postoperative surgical field
CT: Computed tomography, MRI: Magnetic resonance imaging

mutant an IDH2 mutation and 1p/19q loss. The patient was referred to the oncology department. No further genetic tests were performed on the patient. The patient received 60 Gy of curative radiotherapy over one month and was monitored with magnetic resonance imaging (MRI) every three months. The patient did not receive chemotherapy. Twenty months after the initial surgery, gadolinium-enhanced T1-weighted MRI revealed an enlarging mass at the site of the resected oligosarcoma. The mass grew rapidly over 3 months (Figure 2).

Initially diagnosed with recurrent oligosarcoma, he underwent a second surgery 24 months after the first, using the same approach. The tumor was also resected macroscopically during the second surgery. After the second surgery, histopathological examination again reported oligosarcoma. The patient had no preoperative or postoperative neurological deficits. He continues his oncological treatment as an outpatient.

Discussion

Oligosarcomas are generally defined as late complications of previously treated oligodendrogliomas and typically recur at the same anatomic site years after initial surgery. The present case is significant because it represents a primary oligosarcoma. They are frequently located in the frontal and temporal lobes and may present with non-specific symptoms such as headache, epileptic seizures, dizziness, nausea, and vomiting [6-9]. Imaging findings typically appear as solid, heterogeneous masses that are surrounded by significant edema and enhance on T1 with gadolinium. Extra-axial localization or meningeal involvement in oligosarcomas can also be misleading in the differential diagnosis [5]. Histopathologically, these tumors retain the features of oligodendrogliomas (monomorphic round nuclei, perinuclear halo, fine chromatin) while also showing signs of sarcomatous differentiation (eosinophilic cytoplasm, spindle cells, increased mitotic activity, and necrosis). Recurrent oligosarcomas generally reflect high-grade anaplastic morphology with increased cellularity, endothelial hyperplasia, atypical mitoses, hyperchromatic pleomorphic nuclei, and mucus-filled cystic areas [3,6,7,10]. Immunohistochemically, they exhibit glial and mesenchymal features; glial-derived glial fibrillary acidic protein (GFAP) and S-100 positivity, and alpha-smooth muscle actin (α -SMA) and desmin positivity in sarcomatous areas have been reported [6-9].

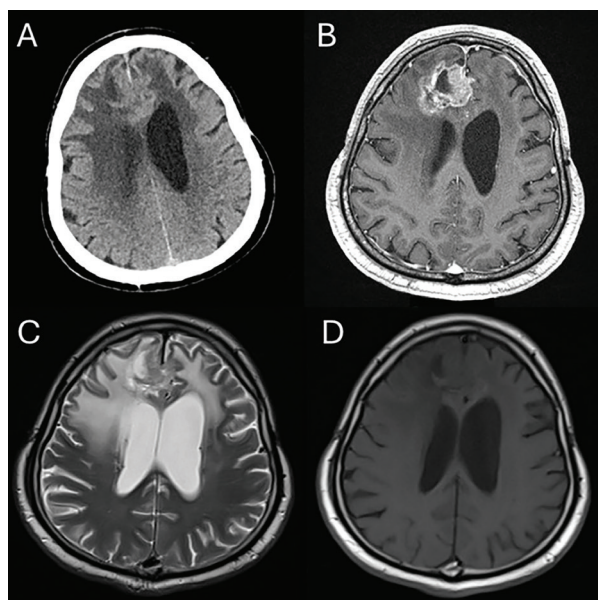


Figure 2. Preoperative images of the second surgery. Computed tomography (A), gadolinium-enhanced T1-weighted (B), T2-weighted (C), and T1-weighted magnetic resonance images (D) revealed a tumor with homogeneous contrast enhancement in the deep portion of the resection cavity

Additionally, publications report cluster of differentiation (CD34) and epithelial membrane antigen (EMA) positivity in sarcomatous areas. Additionally, as Rodriguez et al. [6] demonstrated, positivity for non-GFAP markers (e.g., CD34, α -SMA, EMA) in sarcomatous components can be helpful in the diagnosis of oligosarcoma, and routine evaluation of this panel is recommended during the diagnostic process. In the case presented here, positivity for GFAP, S-100, OLIG-2, and EMA is also noteworthy (Figure 3).

The genetic profile of oligosarcoma can exhibit distinct molecular features that differentiate it from classic oligodendroglioma. Anomalies such as homozygous deletion of *CDKN2A/B* genes, regain of H3K27me3 expression, loss of 6q and *NF1*, and gain of *YAP1* have been frequently reported in these tumors [5]. In the case presented by Tanaka et al. [8], the presence of an IDH1 mutation and a 1p/19q codeletion in both oligodendroglial and sarcomatoid components strongly supports the oligodendroglial origin of the tumor and the development of a sarcomatoid component as a result of metaplastic transformation. In glial tumors, IDH1 mutations are more common than IDH2 mutations. Although IDH' mutations are rare, they are more common in oligodendrogliomas [11]. The presence of the rare IDH2 mutation in our case is noteworthy.

The main treatment approach is maximal safe surgical resection followed by adjuvant therapy. Conventional treatment comprises procarbazine, lomustine, and vincristine (PCV), together with radiotherapy. However, based on long-term data, the PCV regimen is preferred in some centers [12]. According to recent reports, despite aggressive surgery and adjuvant chemoradiotherapy, the median survival after oligosarcoma diagnosis has been reported as only 1.3 years (range, 0-5.2 years), confirming the poor prognosis of the disease [5]. The presence of the 1p/19q codeletion is associated with a better response to chemotherapy and radiotherapy and is considered a favorable prognostic factor [6,13]. The patient survived for 24 months, which is above the mean survival time. The primary explanation for this is 1p/19q codeletion. This genetic alteration is associated with a better prognosis in oligodendrogliomas. It contributes to the slower progression of the tumor and a better response to chemotherapy/radiotherapy [14]. The patient presented in this case was diagnosed with oligosarcoma without any prior history of surgery or oncologic treatment, suggesting that sarcomatous features may develop *de novo* in some cases.

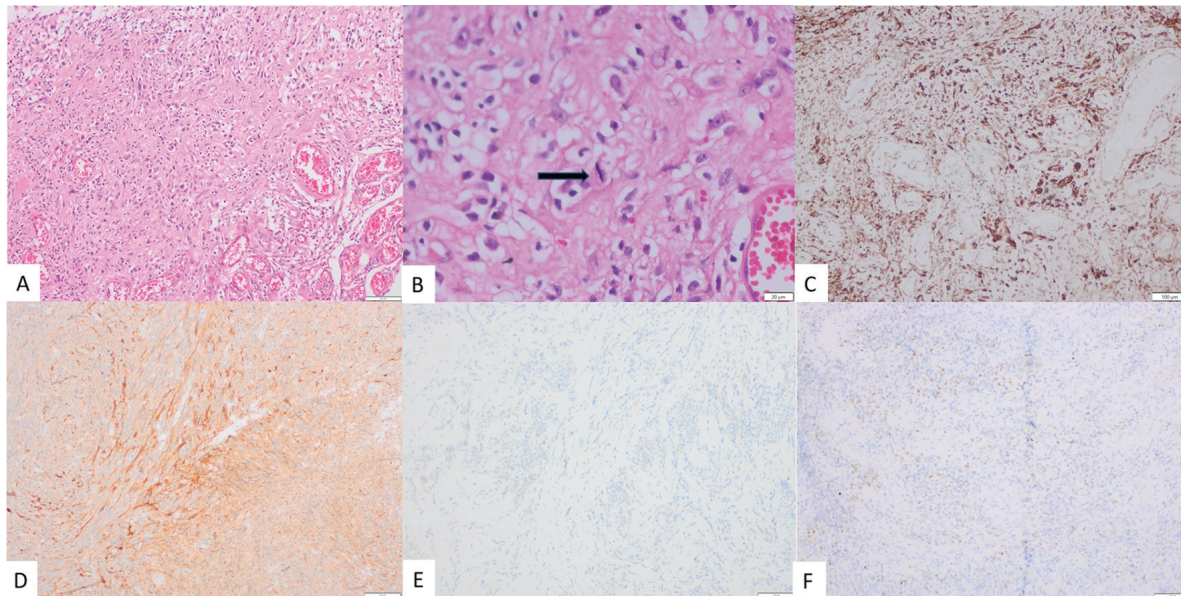


Figure 3. Oligosarcoma. A: Hematoxylin eosin, 100x. B: Hematoxylin eosin, 400x (black arrow: atypical mitosis). C: GFAP, 100x. D: S-100, 100x. E: EMA, 100x. F: OLIG-2, 100x
GFAP: Glial fibrillary acidic protein, OLIG-2: Oligodendrocyte transcription factor 2

Ethics

Informed Consent: Informed consent was obtained from all patients included in the study.

Footnotes

Authorship Contributions

Surgical and Medical Practices: M.Ş.S., M.E.Y., N.K., M.F.E., Concept: M.F.E., Design: M.Ş.S., M.F.E., Data Collection or Processing: M.Ş.S., N.K., Analysis or Interpretation: M.E.Y., N.K., Literature Search: M.Ş.S., M.E.Y., Writing: M.Ş.S., M.E.Y.

Conflict of Interest: No conflict of interest was declared by the authors.

Financial Disclosure: The authors declared that this study received no financial support.

References

1. Engelhard HH. Current diagnosis and treatment of oligodendroglioma. *Neurosurg Focus*. 2002;12:E2.
2. van den Bent MJ, Kros JM, Heimans JJ, et al. Response rate and prognostic factors of recurrent oligodendroglioma treated with procarbazine, CCNU, and vincristine chemotherapy. Dutch Neuro-oncology Group. *Neurology*. 1998;51:1140-1145.
3. Engelhard HH, Stelea A, Mundt A. Oligodendroglioma and anaplastic oligodendroglioma: clinical features, treatment, and prognosis. *Surg Neurol*. 2003;60:443-456.
4. Wesseling P, van den Bent M, Perry A. Oligodendroglioma: pathology, molecular mechanisms and markers. *Acta Neuropathol*. 2015;129:809-827.
5. Evans AR, Prather KY, Battiste J, Fung KM, Dunn IF, Graffeo CS. Genetically distinct oligosarcoma arising from oligodendroglioma: systematic review & illustrative case example. *World Neurosurg*. 2024;185:e1093-e1100.
6. Rodriguez FJ, Scheithauer BW, Jenkins R, et al. Gliosarcoma arising in oligodendroglial tumors ("oligosarcoma"): a clinicopathologic study. *Am J Surg Pathol*. 2007;31:351-362.
7. Yasuda T, Nitta M, Komori T, et al. Gliosarcoma arising from oligodendroglioma, IDH mutant and 1p/19q codeleted. *Neuropathology*. 2018;38:41-46.
8. Tanaka S, Hitotsumatsu T, Sugita Y, et al. Gliosarcoma arising from oligodendroglioma (oligosarcoma): a case report with genetic analyses. *Pathol Int*. 2018;68:567-573.
9. Fadda A, Vajtai I, Lang J, Henke D, Oevermann A. Cerebral high-grade oligodendroglioma with sarcomatous transdifferentiation ("oligosarcoma") in a boxer dog. *J Vet Intern Med*. 2014;28:1881-1885.
10. Vajtai I, Vassella E, Hewer E, Kappeler A, Reinert MM. Sarcomatous evolution of oligodendroglioma ("oligosarcoma"): confirmatory report of an uncommon pattern of malignant progression in oligodendroglial tumors. *Pathol Res Pract*. 2012;208:750-755.
11. Hartmann C, Meyer J, Balss J, et al. Type and frequency of IDH1 and IDH2 mutations are related to astrocytic and oligodendroglial differentiation and age: a study of 1,010 diffuse gliomas. *Acta Neuropathol*. 2009;118:469-474.
12. Ohgaki H, Kleihues P. Population-based studies on incidence, survival rates, and genetic alterations in astrocytic and oligodendroglial gliomas. *J Neuropathol Exp Neurol*. 2005;64:479-489.
13. Bromberg JE, van den Bent MJ. Oligodendrogliomas: molecular biology and treatment. *Oncologist*. 2009;14:155-163.
14. Hacısalihoglu P, Kucukodaci Z, Gundogdu G, Bilgic B. The correlation between 1p/19q codeletion, IDH1 mutation, p53 overexpression and their prognostic roles in 41 Turkish anaplastic oligodendroglioma patients. *Turk Neurosurg*. 2017;27:682-689.